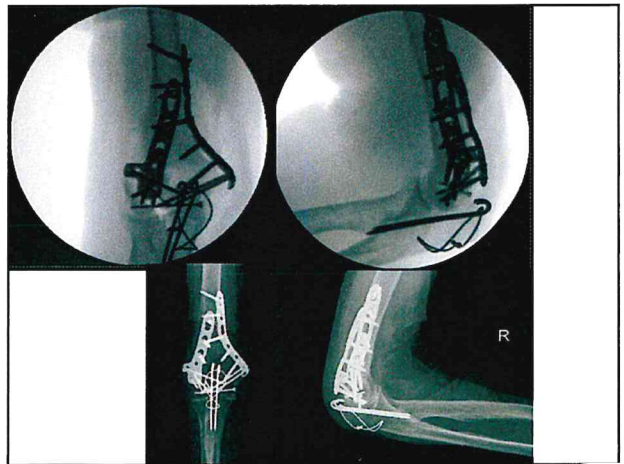
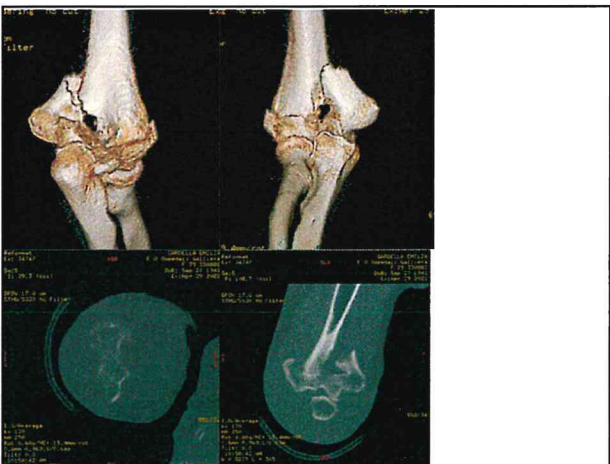
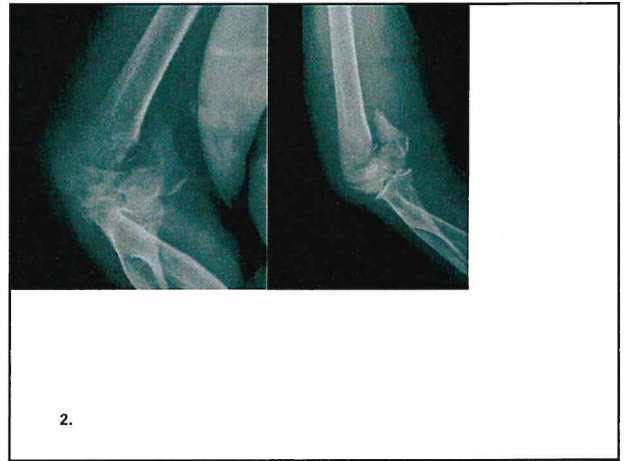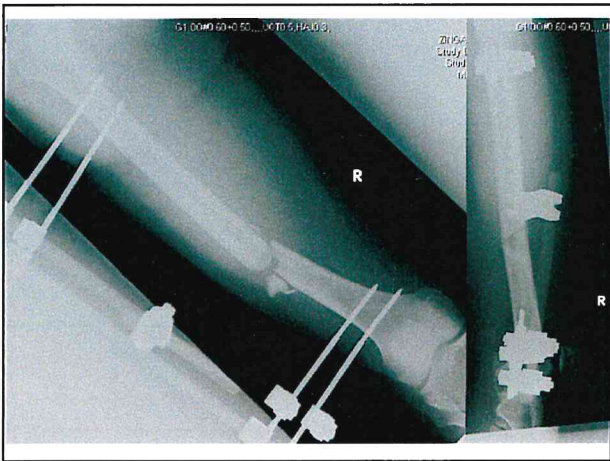
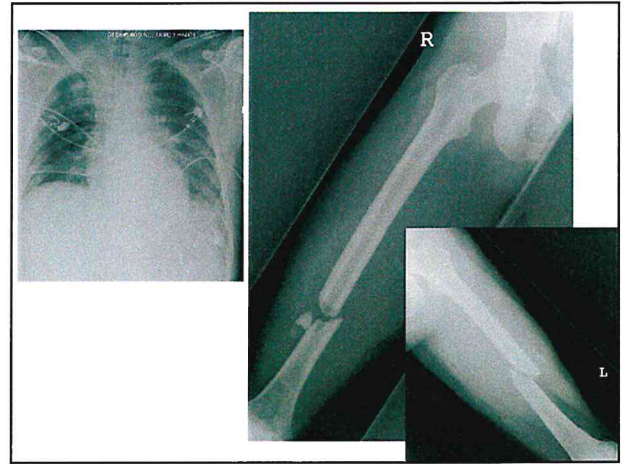
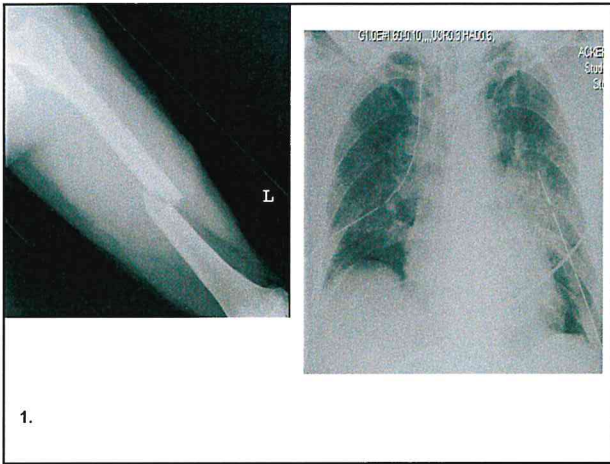
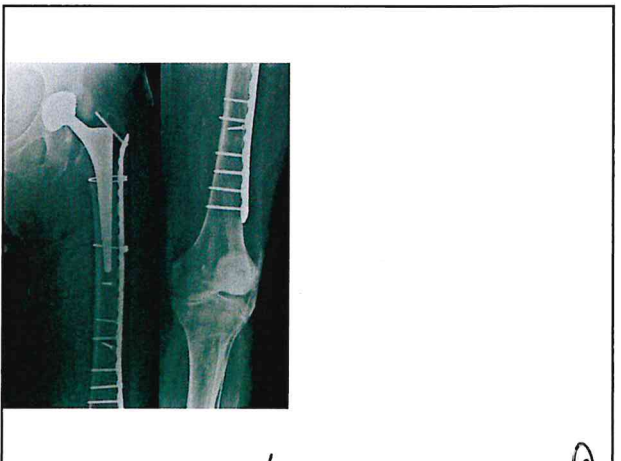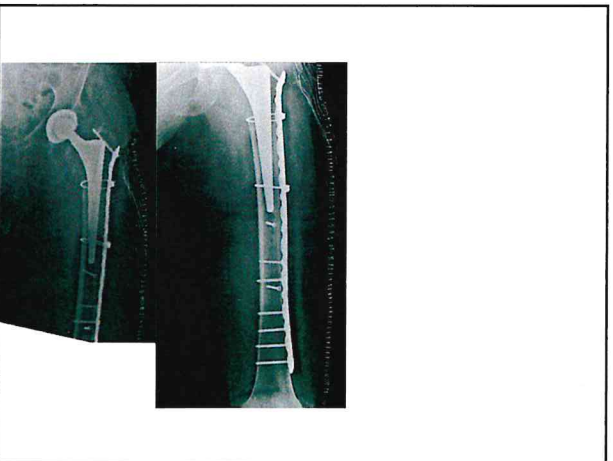

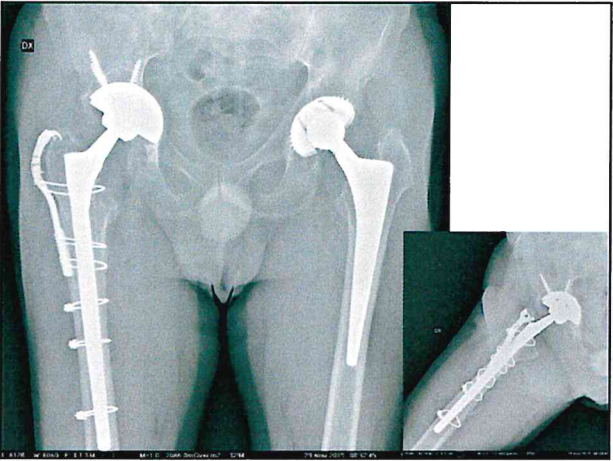
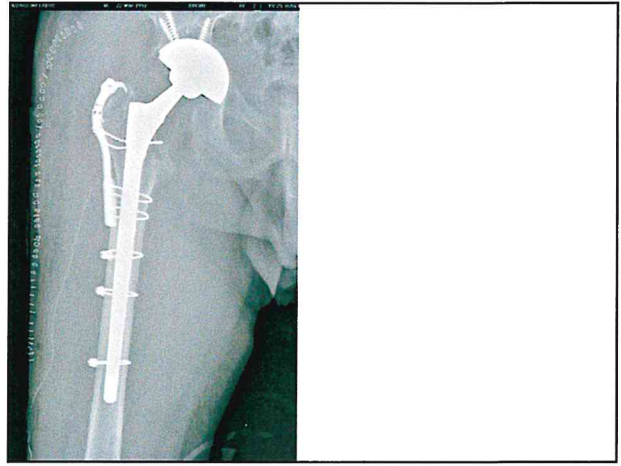
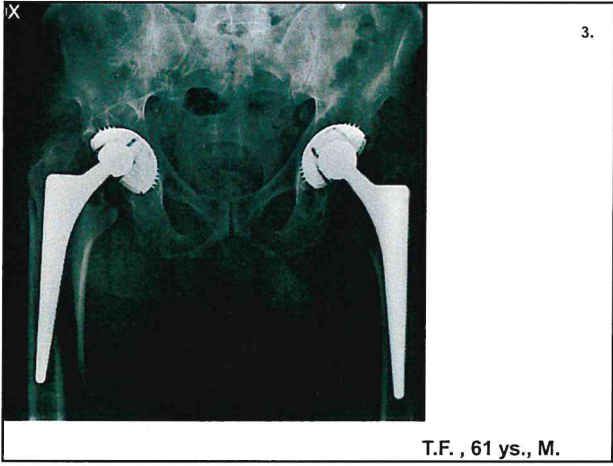


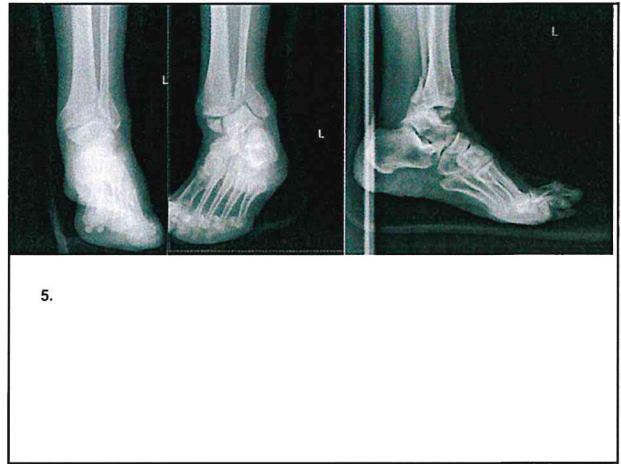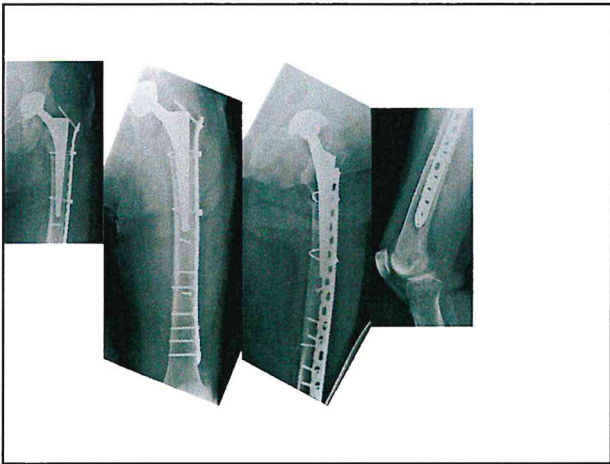
Prova ~~orale~~ Casi clinici

- 1 Frattura diafisaria di femore in paziente politraumatizzato
- 2 Frattura omero distale
- 3 Frattura periprotetica anca
- 4 Frattura periprotetica anca
- 5 Frattura malleolare caviglia
- 6 Frattura gamba trauma ad alta energia
- 7 Frattura acetabolo
- 8 Frattura piatto tibiale
- 9 Frattura periprotetica di ginocchio
- 10 Frattura diafisaria omero distale
- 11 Frattura pilone tibiale
- 12 Frattura polso

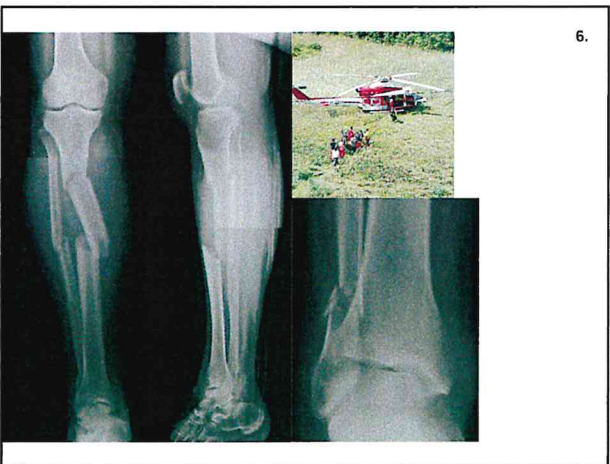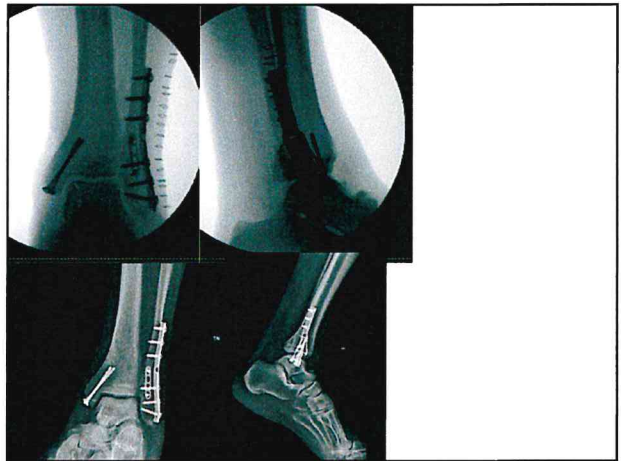

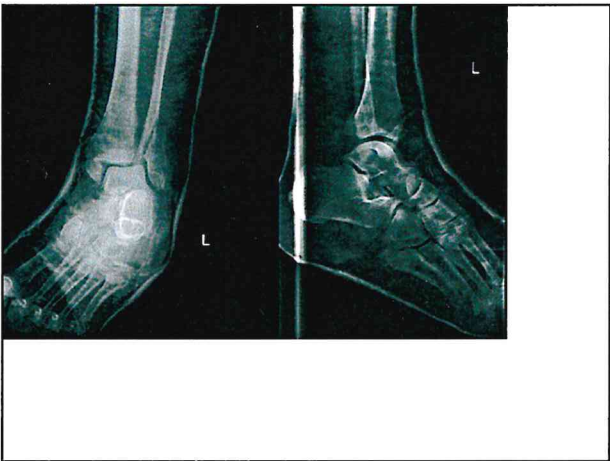




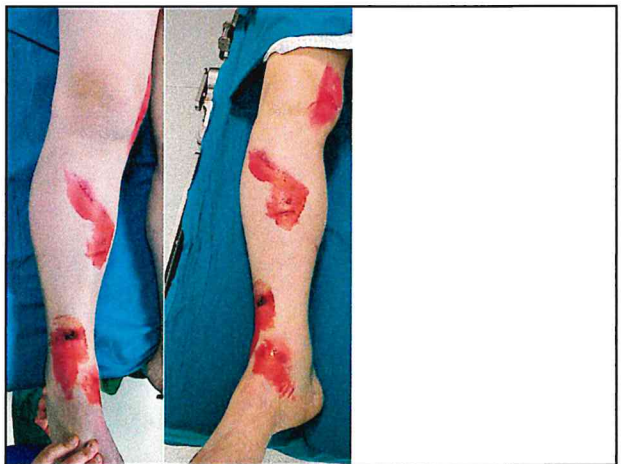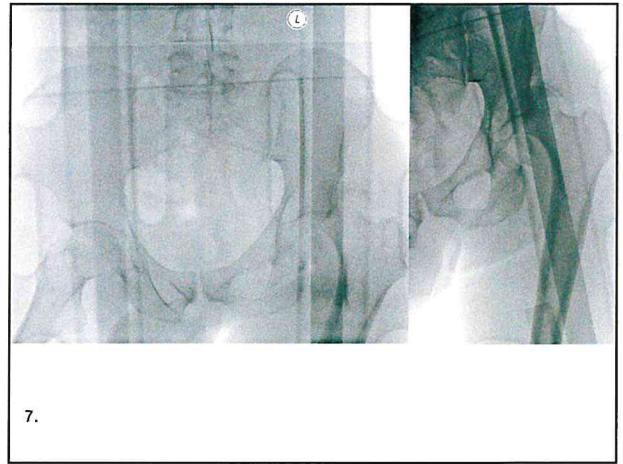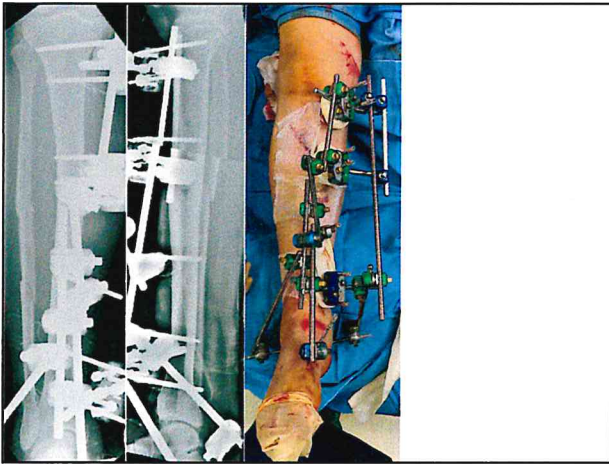


5.

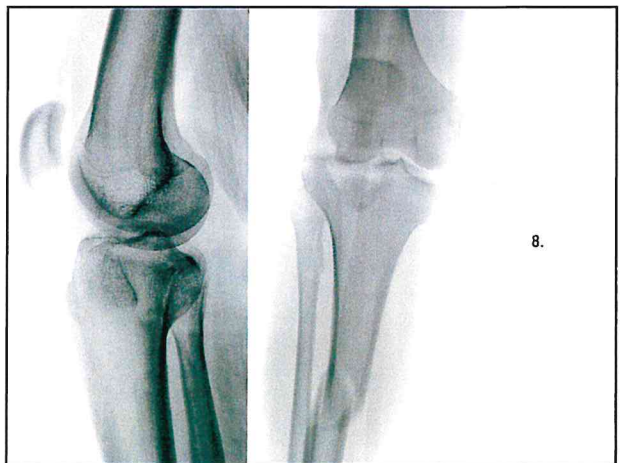
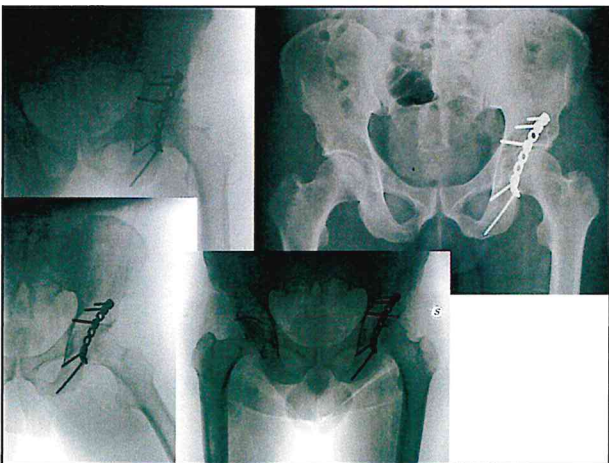
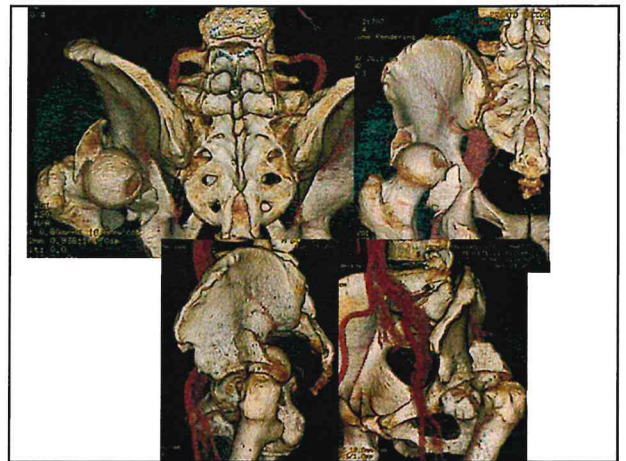
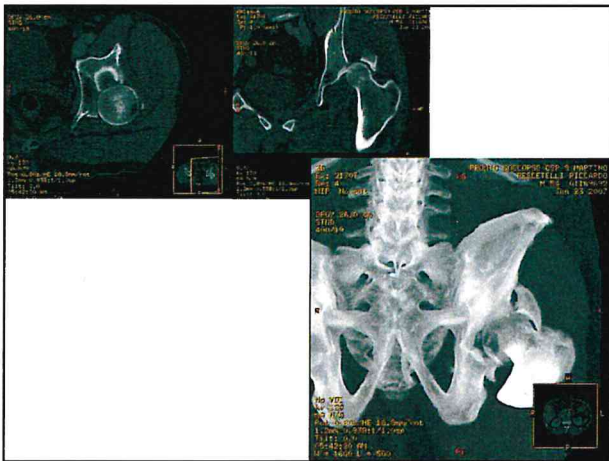


6.





7.



8.



