

34

allegato 2
Prava non esult

1.

DATI ANAMNESTICI:

Donna di 65aa con recente lutto in famiglia.

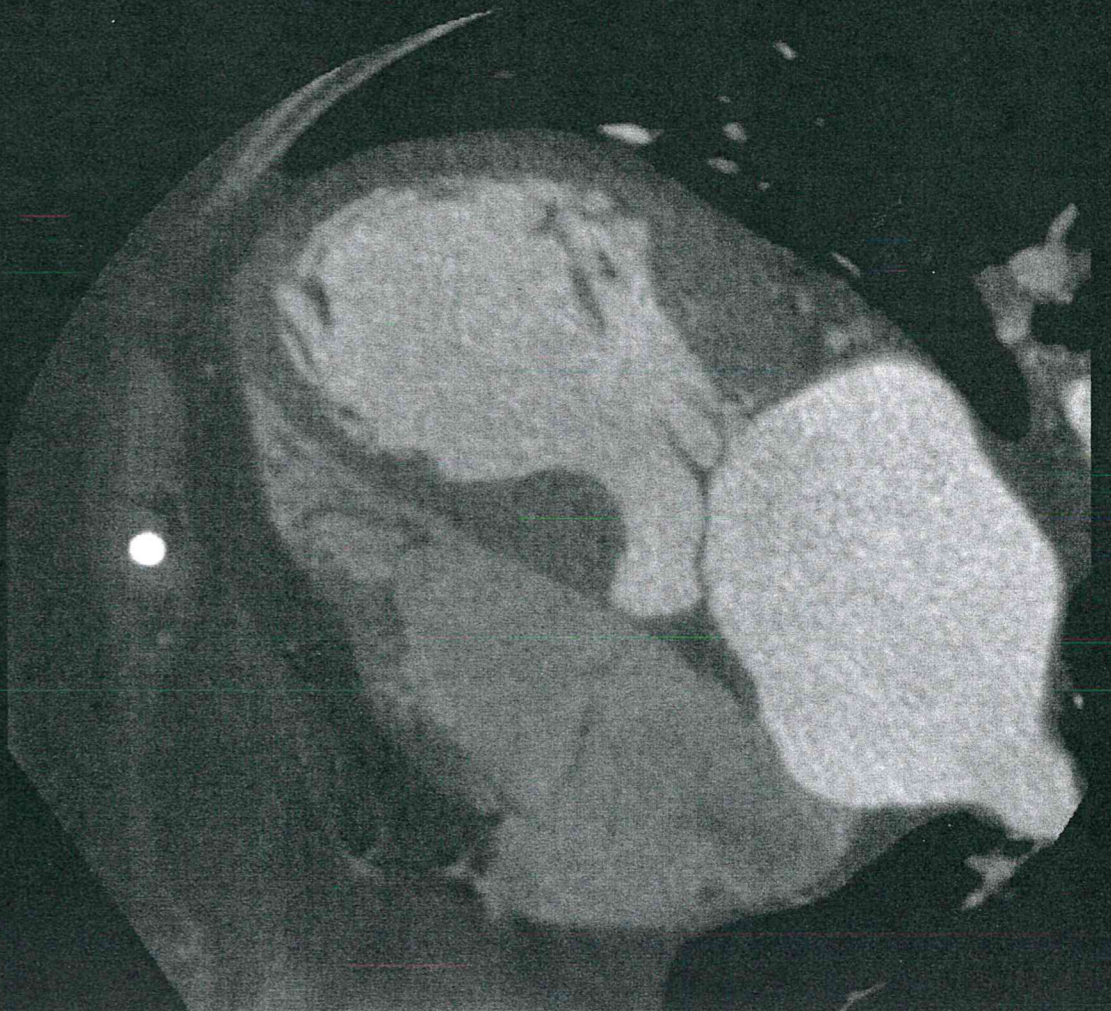
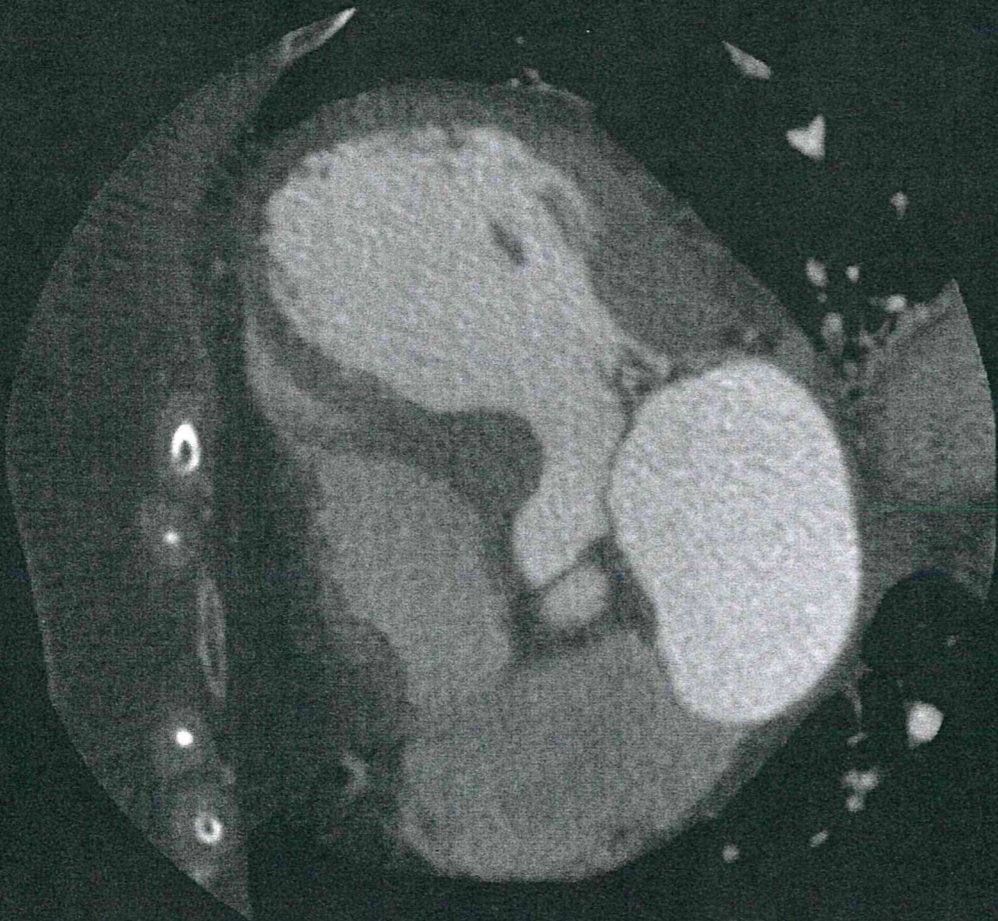
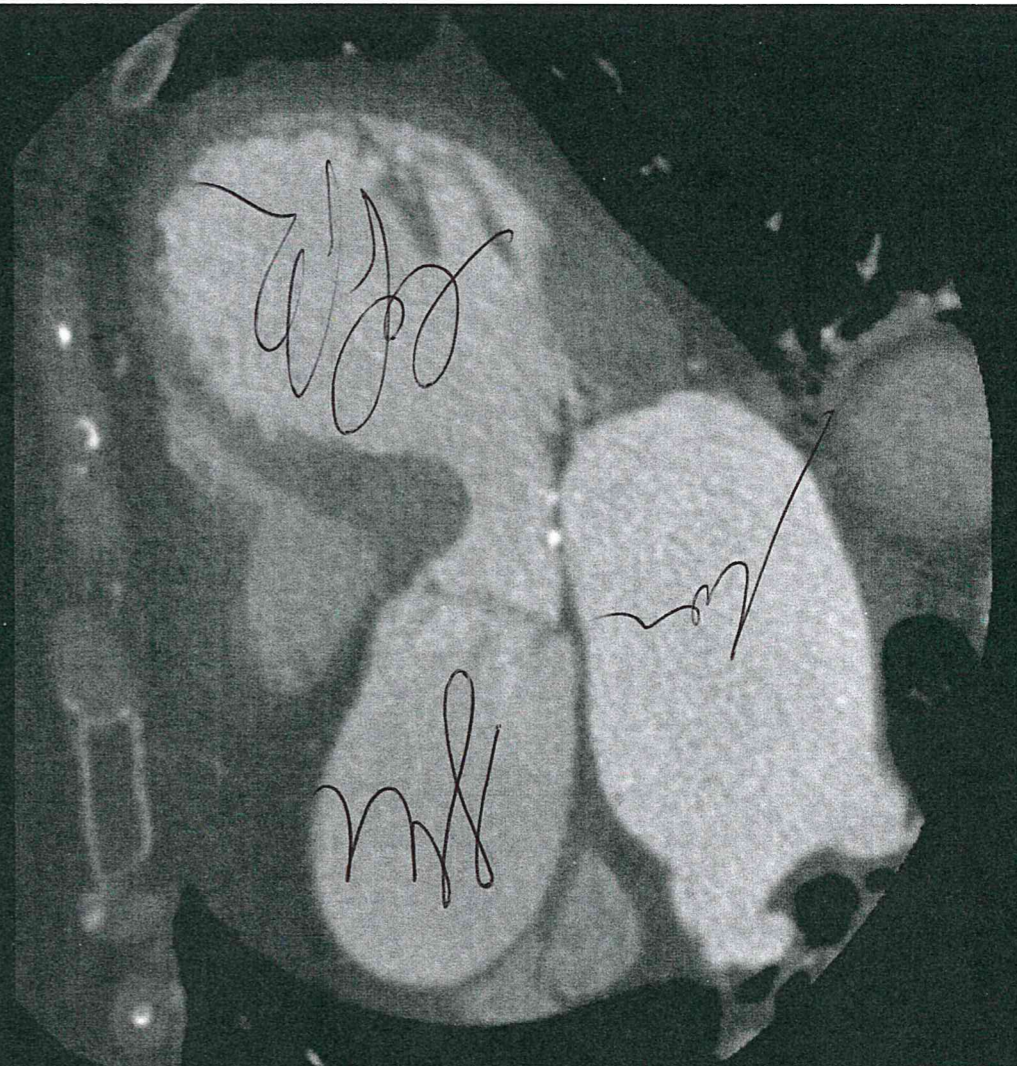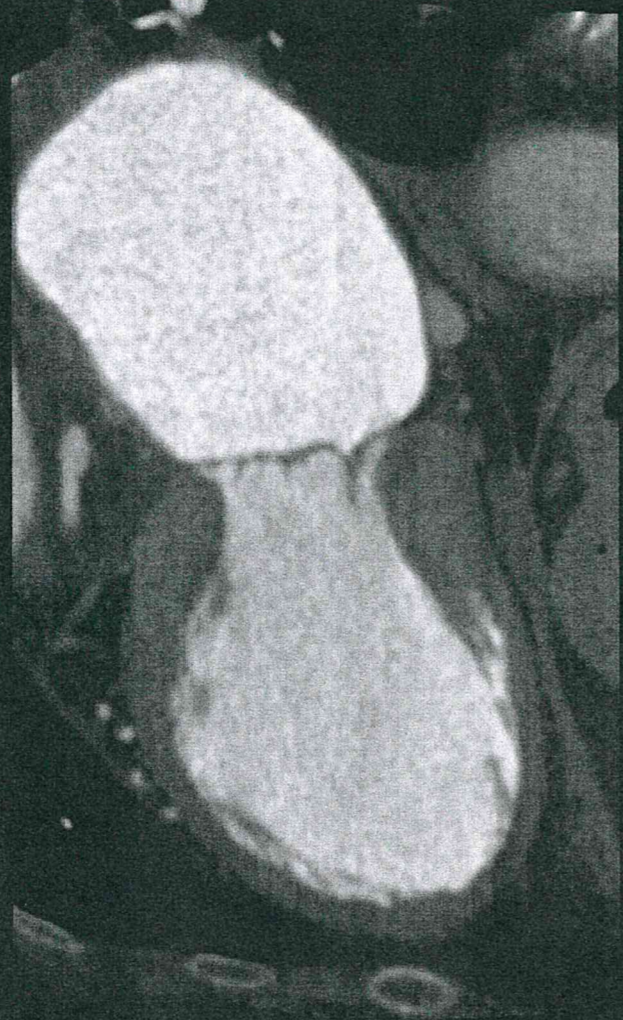
Dolore precordiale insorto acutamente

Minimo incremento dei biomarcatori cardiaci





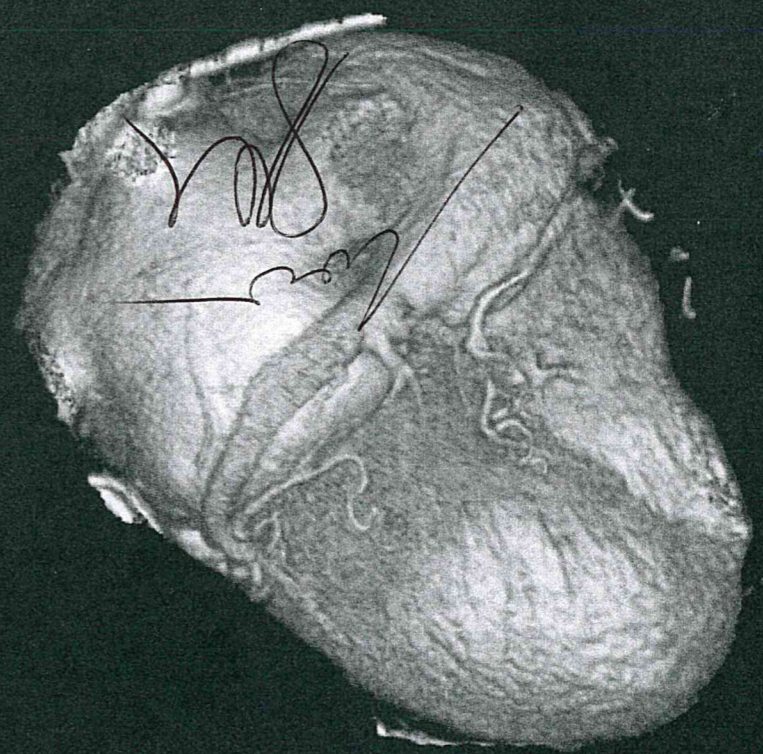
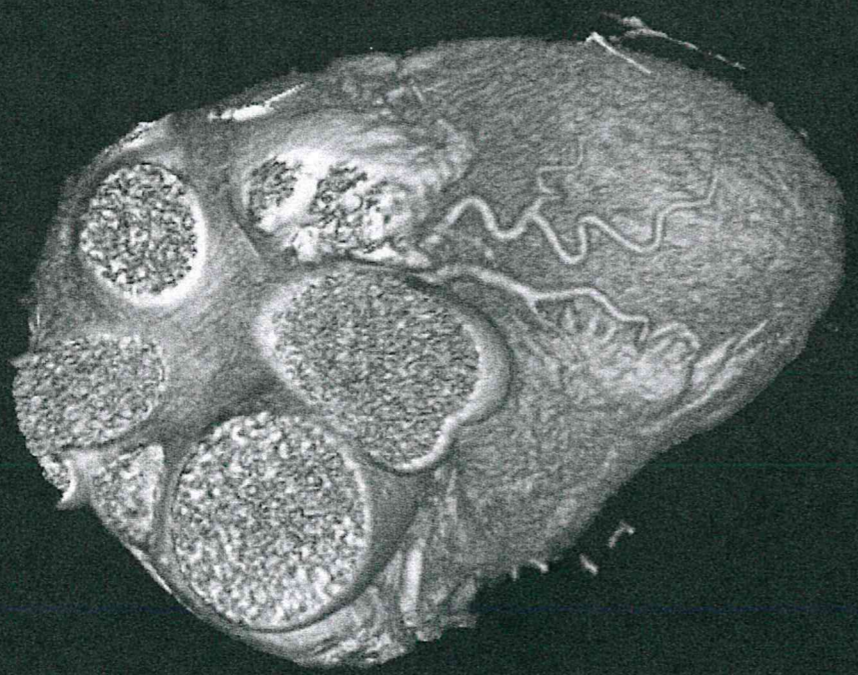
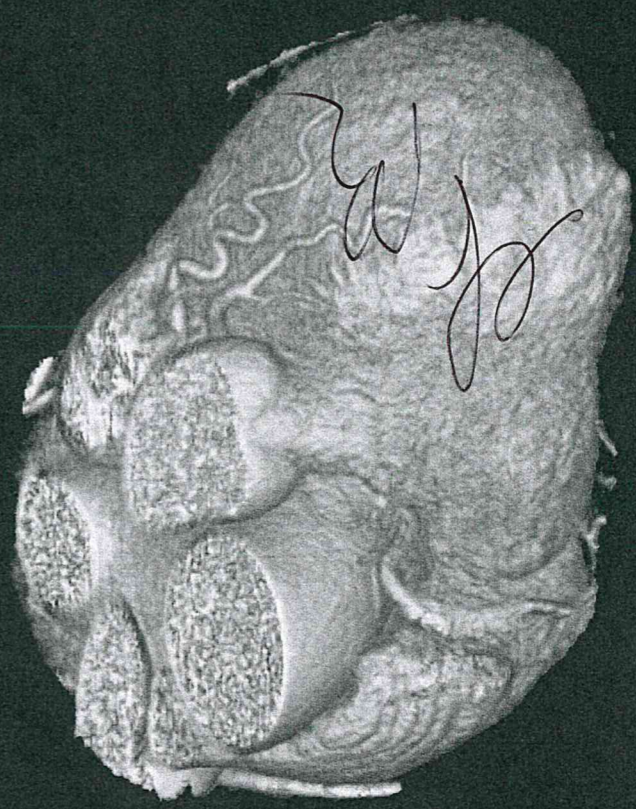
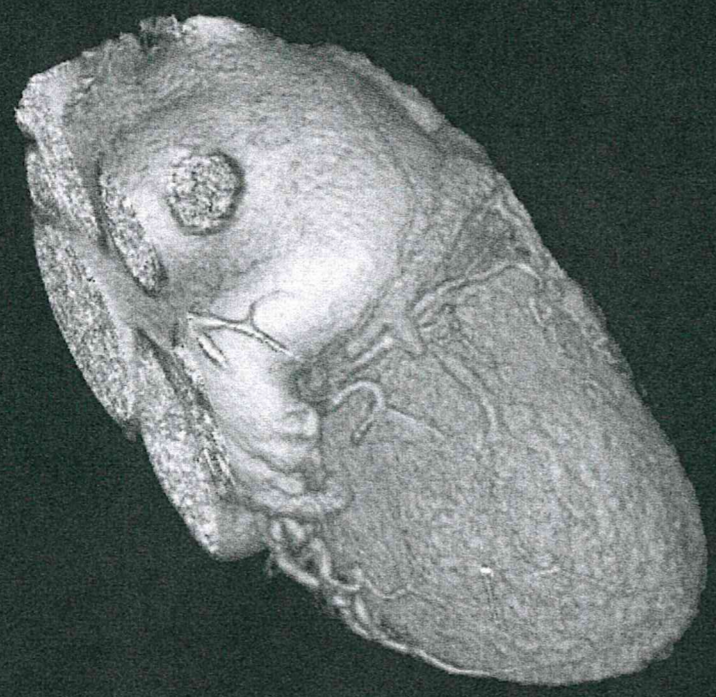


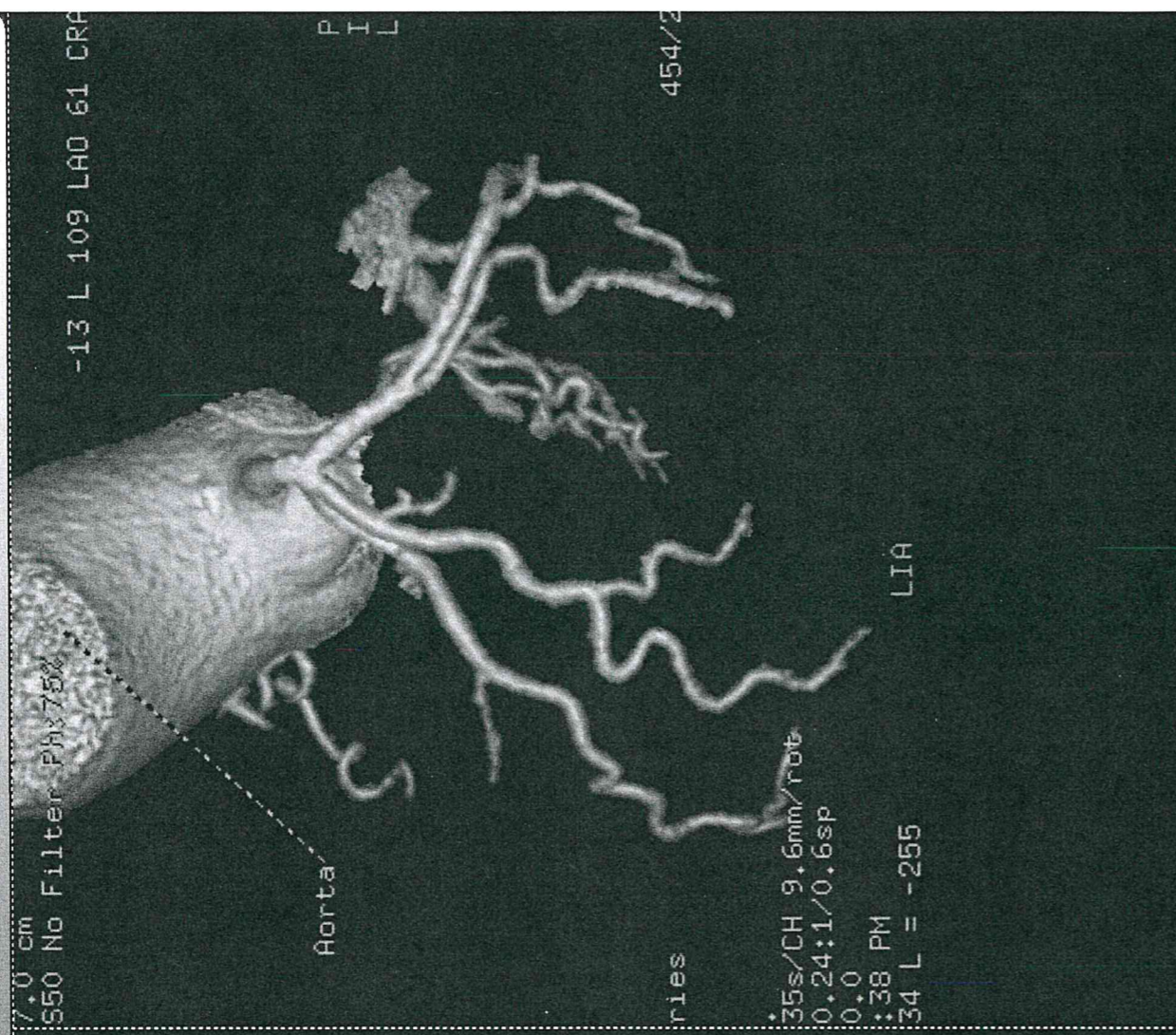
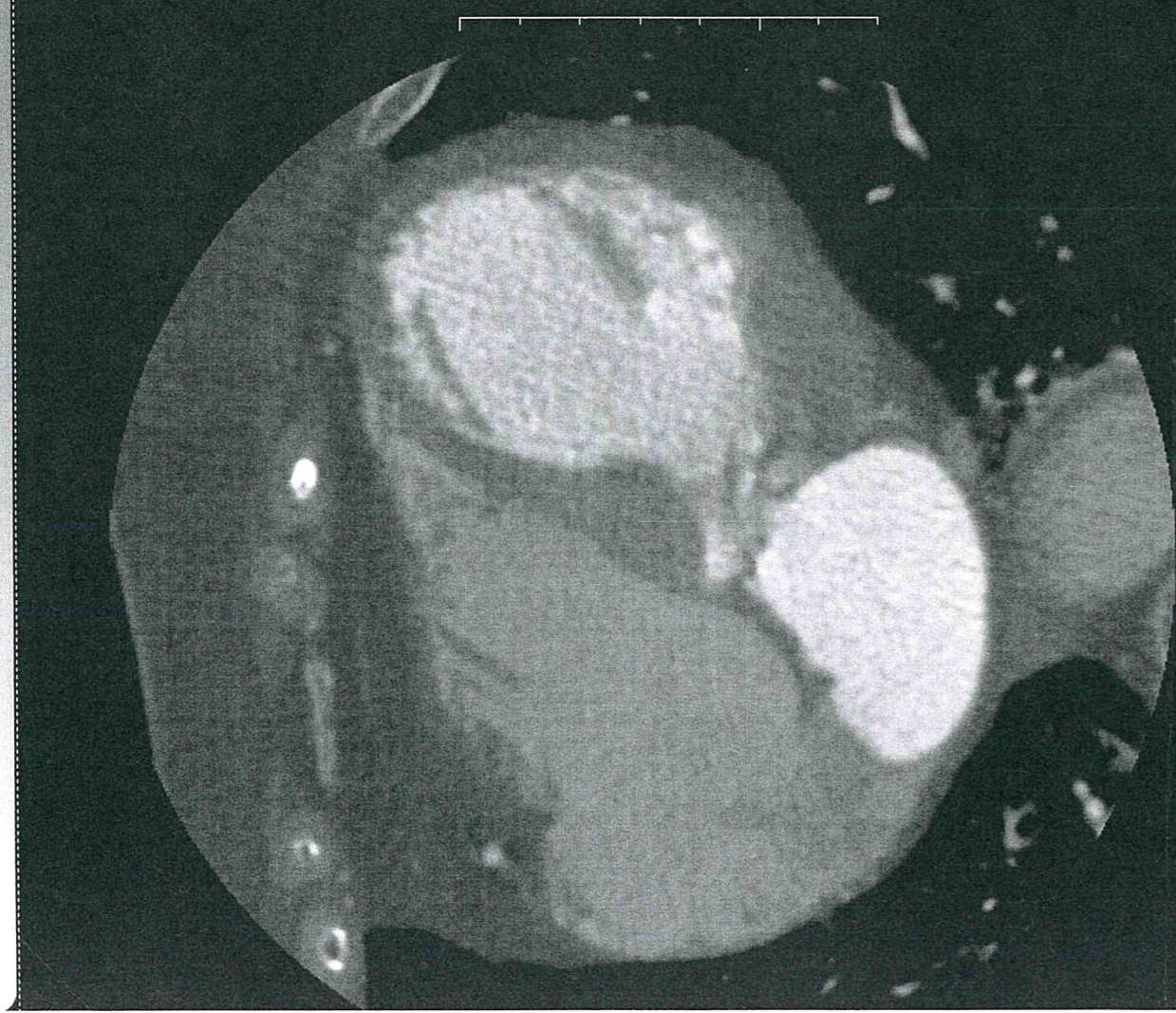


1/1

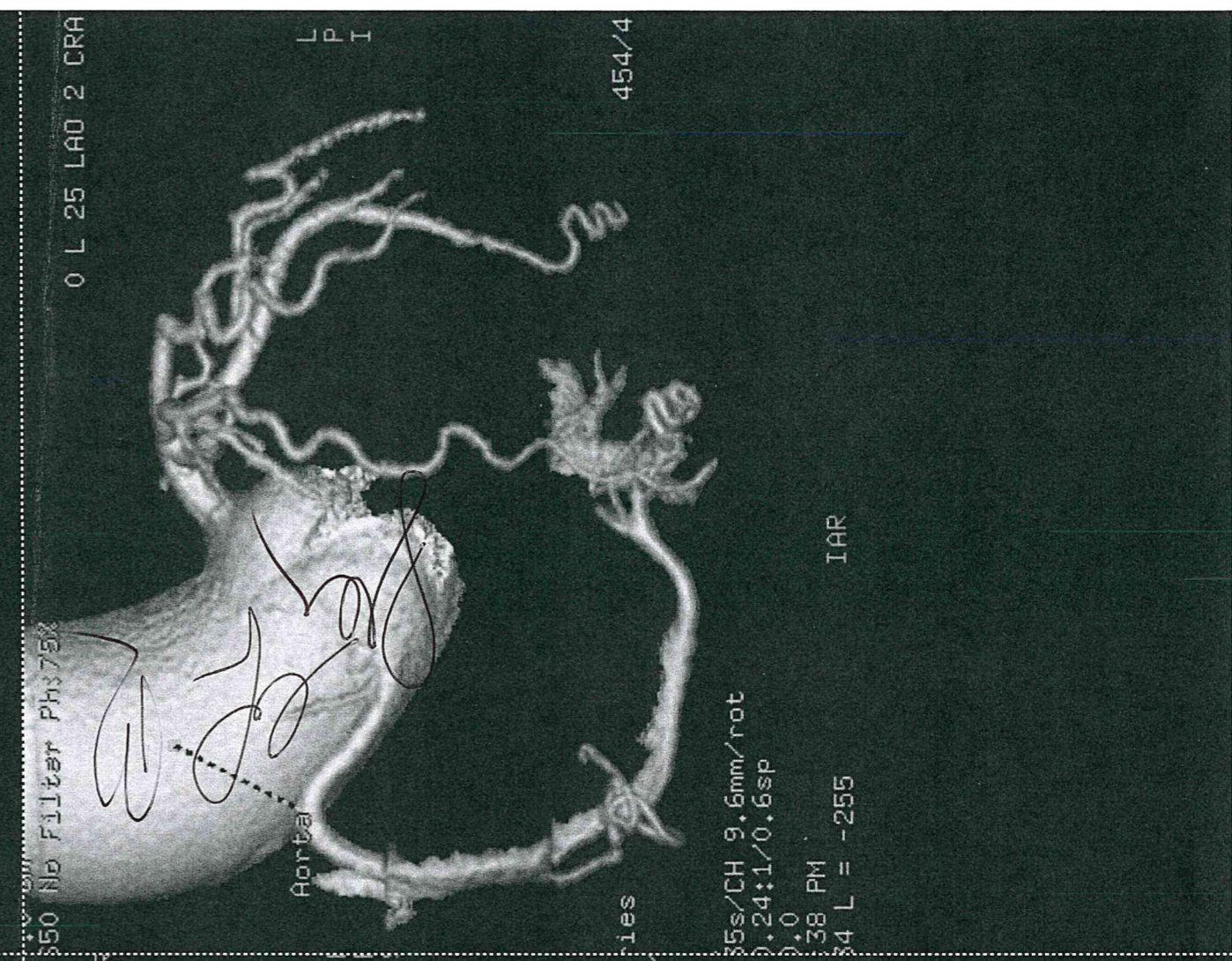
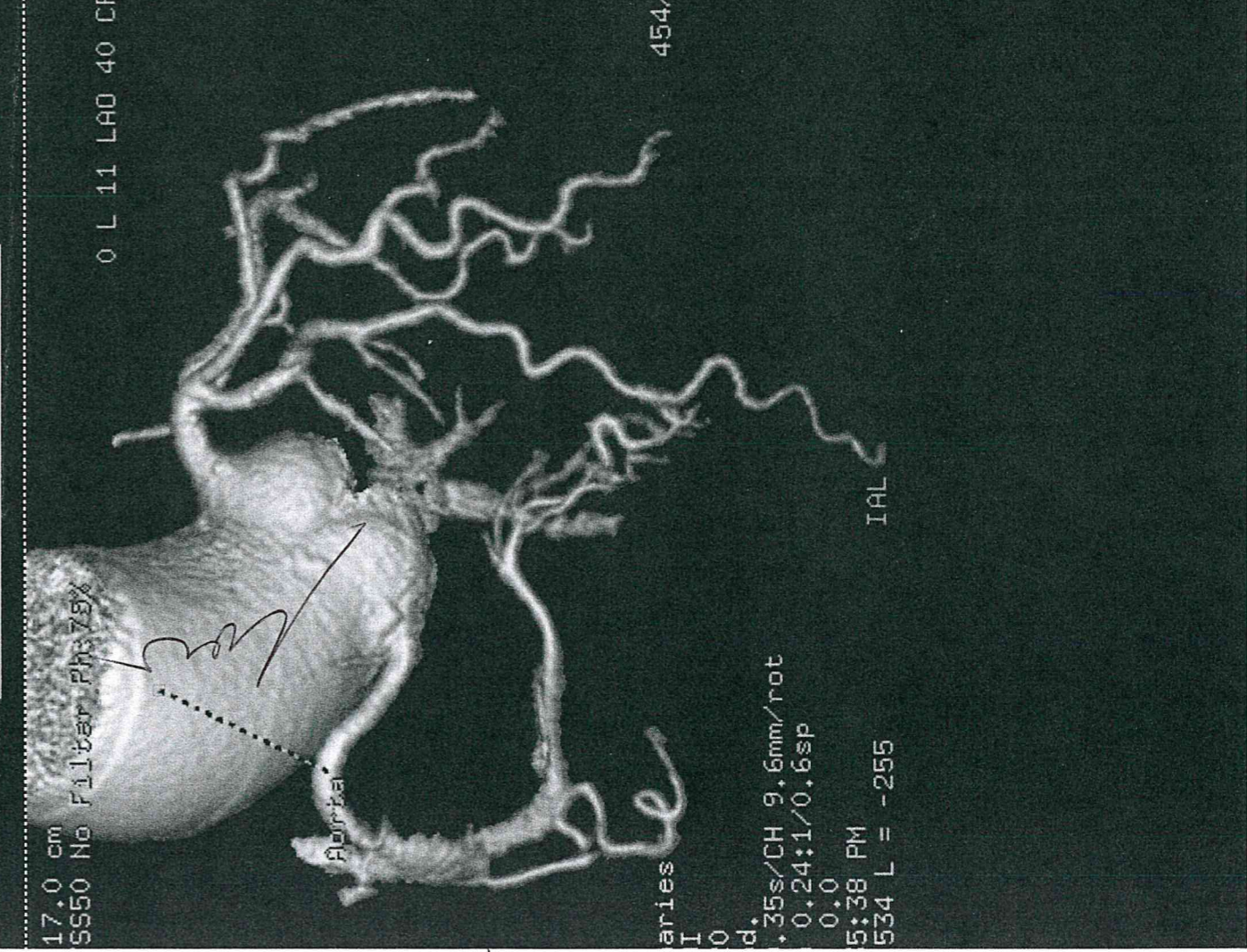
55

2/2





7.0 cm
 550 No Filter Phs75%
 -13 L 109 LAD 61 CRA
 P
I
L
 454/2
 Aorta
 LIA
 35s/CH 9.6mm/rot
 0.24:1/0.6sp
 0.0
 5:38 PM
 534 L = -255



17.0 cm
 550 No Filter Phs75%
 0 L 11 LAD 40 CR
 454/4
 Aorta
 IAL
 35s/CH 9.6mm/rot
 0.24:1/0.6sp
 0.0
 5:38 PM
 534 L = -255

7.0 cm
 550 No Filter Phs75%
 0 L 25 LAD 2 CRA
 L
P
I
 454/4
 Aorta
 IAR
 35s/CH 9.6mm/rot
 0.24:1/0.6sp
 0.0
 5:38 PM
 534 L = -255

3.

DATI ANAMNESTICI

45aa

Massa pulsante laterocervicale, tachicardia, cefalea e disfagia.

per prova mm or hbd

per prova def M

3 / 3

Sagittal
Ex:1

Se:3
R: 26.9

DFOV17.2cm
STND

S 40

Diagnostica x Imm IST Genova
F 80 0003836
Ex:Oct 09 201

A
1
5
3

DCA:OFF

2.65/Average
kV 120
mA Mod.
Rot 0.50s/HE 55.0mm/rot
1.2mm 1.375:11.25sp
Tilt:0.0
03:37:31 PM
W =270 L =125

I 132
SAL

3D
Ex:1

Se:3
Volume Rendering No cut

DFOV26.0cm
STND

Diagnostica x Imm IST Genova
F 80 00038368
Ex:Oct 09 2018

83

PR S

No VOI
kV 120
mA Mod.
Rot 0.50s/HE 55.0mm/rot
1.2mm 1.375:11.25sp
Tilt:0.0
03:37:31 PM
W =270 L =125

A
L
I

IPR

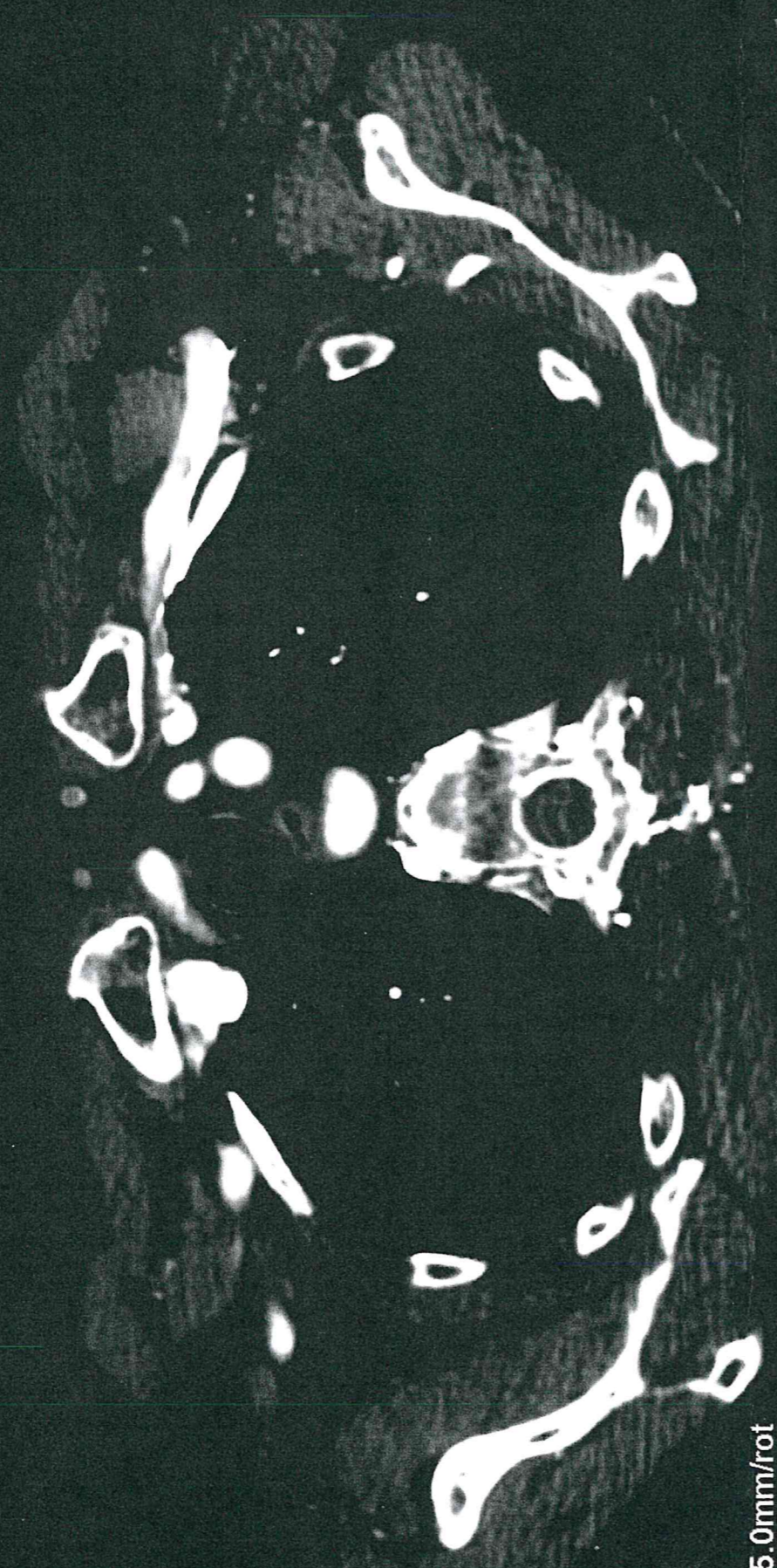1 / 2

Axial
Ex:1

A 85

Diagnostica x Imm IST Genova
Ex: Oct 09 2018

Se:3
I: 112.0
Im:149
DFOV24.9cm
STND



R 1 8 9

L 1 9 6

DCA:OFF

1.25
kV 120
mA493
Rot 0.50s/HE 55.0mm/rot
1.2mm 1.375:1/1.25sp
Tilt:0.0
03:37:31 PM
W = 270 L = 125

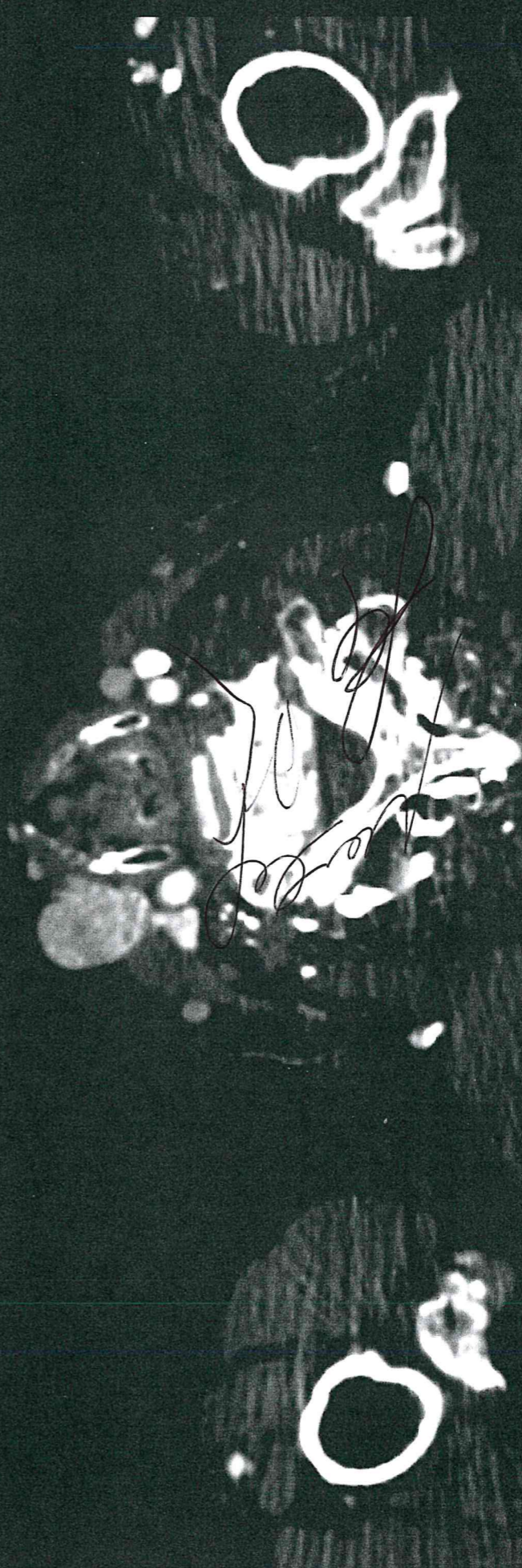P 164
A 85

Axial
Ex:1

Diagnostica x Imm IST Genova
F 80 00038368

Se:3
I: 47.0
Im:97

DFOV24.9cm



R 1 8 9

L 1 9 6

DCA:OFF

1.25

1.2mm 1.375:1/1.25sp
03:37:31 PM
W = 270 L = 125

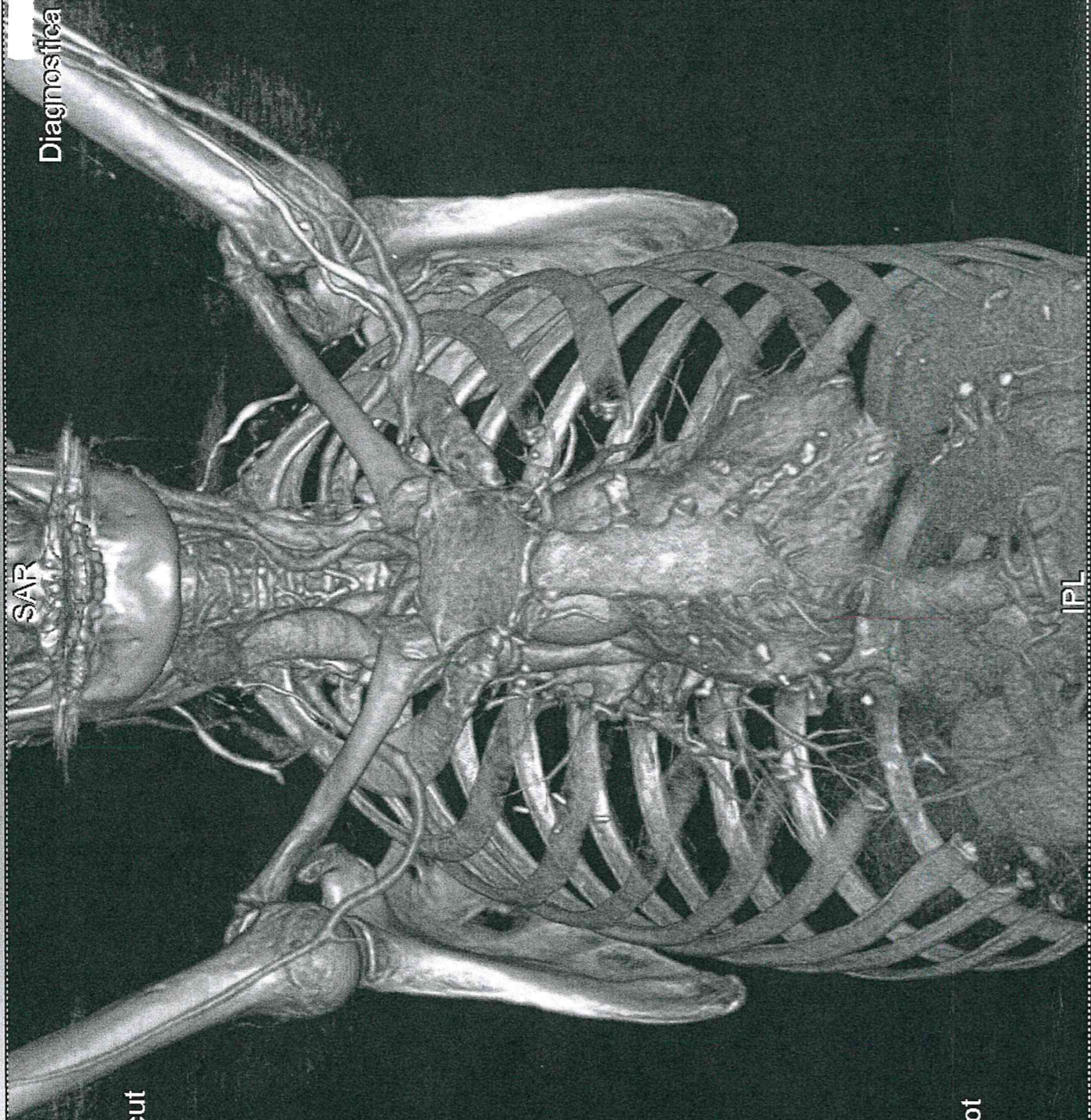
P 164

2 / 2

3D
Ex:1

Se:3
Volume Rendering No cut
DFOV39.9cm
STND

SAR
Diagnostica x Imm IST Genova
F 80 00038368



R P I

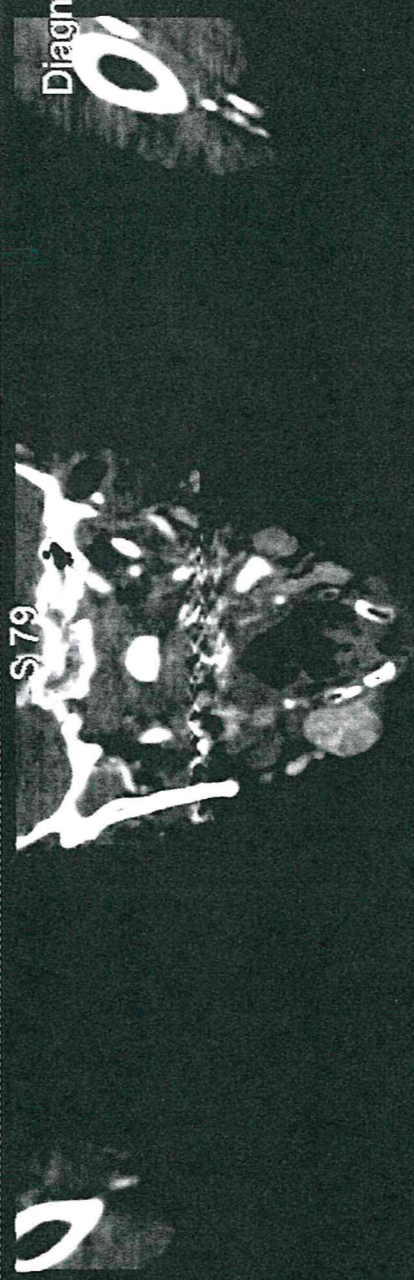
L A S

No VOI
kV 120
mA Mod.
Rot 0.50s/HE 55.0mm/rot
1.2mm 1.375:1/1.25sp
Tilt:0.0
03:37:31 PM
W=270 L=125

Coronal
Ex:1

Se:3
A: 10.3

DFOV48.8cm
STND

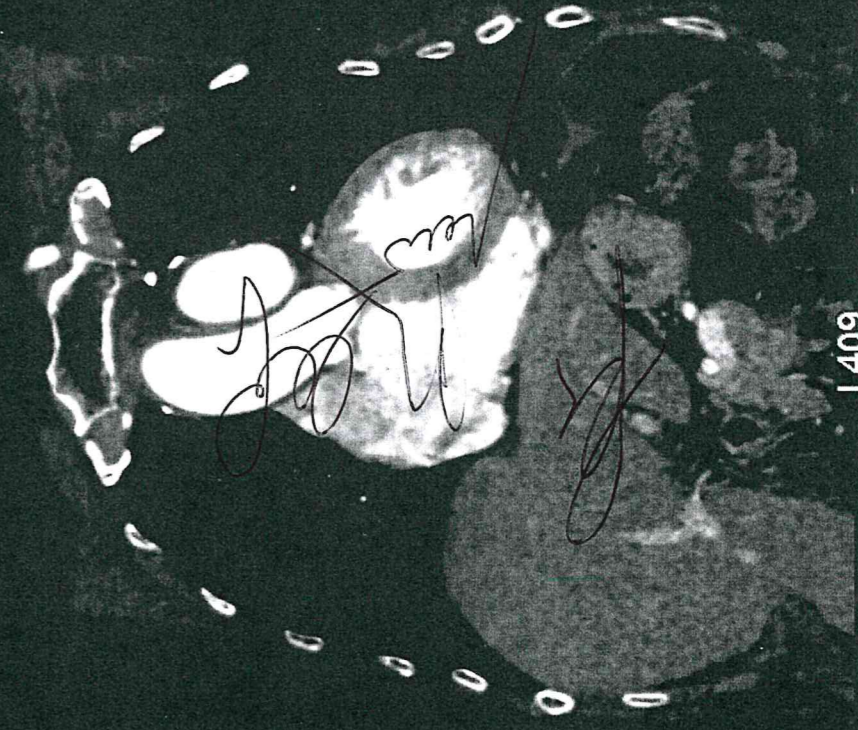


979

Diagnostica x Imm IST Genova
F 80 00038368
Ex:Oct 09 2018

R 374

L 381



DCA:OFF

0.88
kV 120
mA Mod.
Rot 0.50s/HE 55.0mm/rot
1.2mm 1.375:1/1.25sp
Tilt:0.0
03:37:31 PM
W=270 L=125

409

55