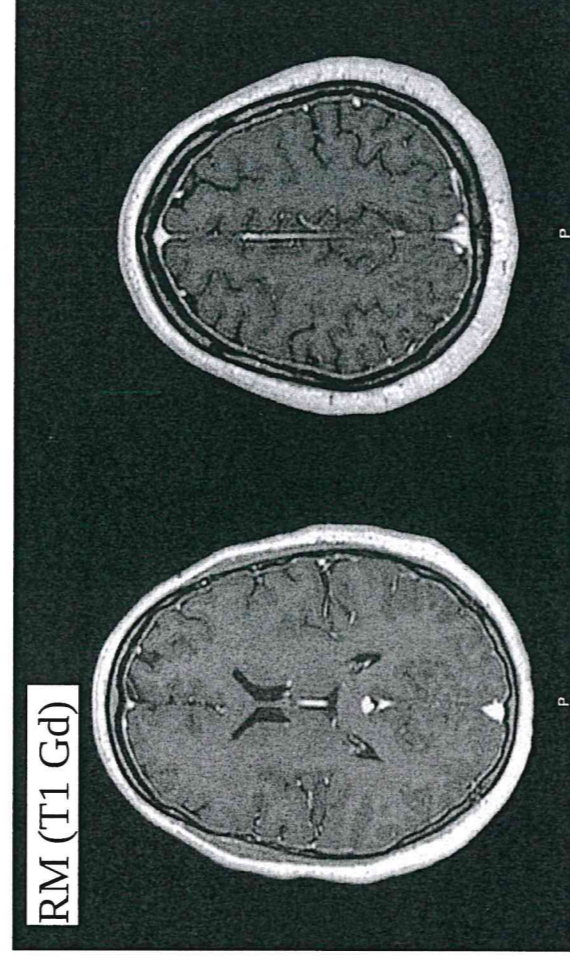
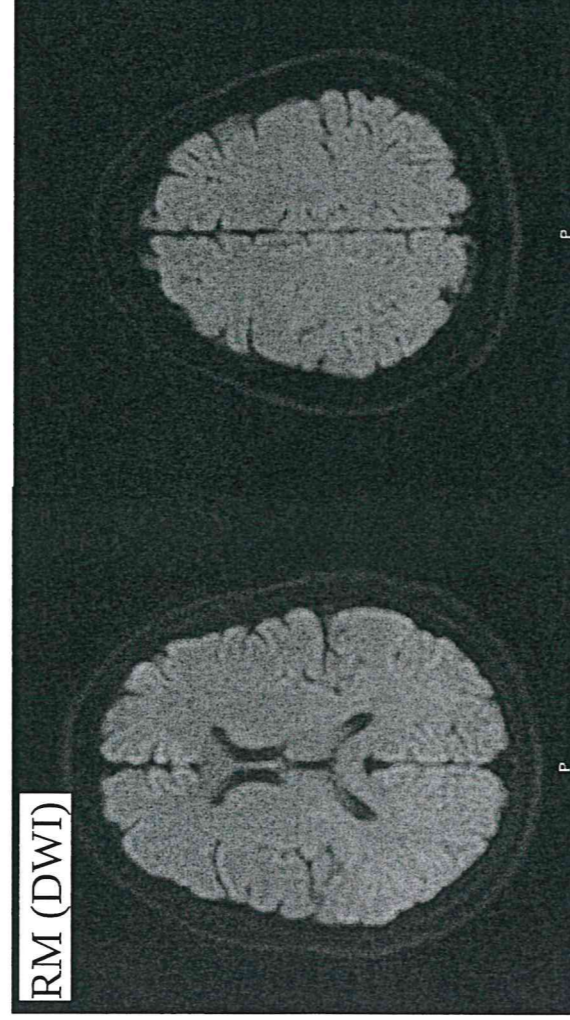
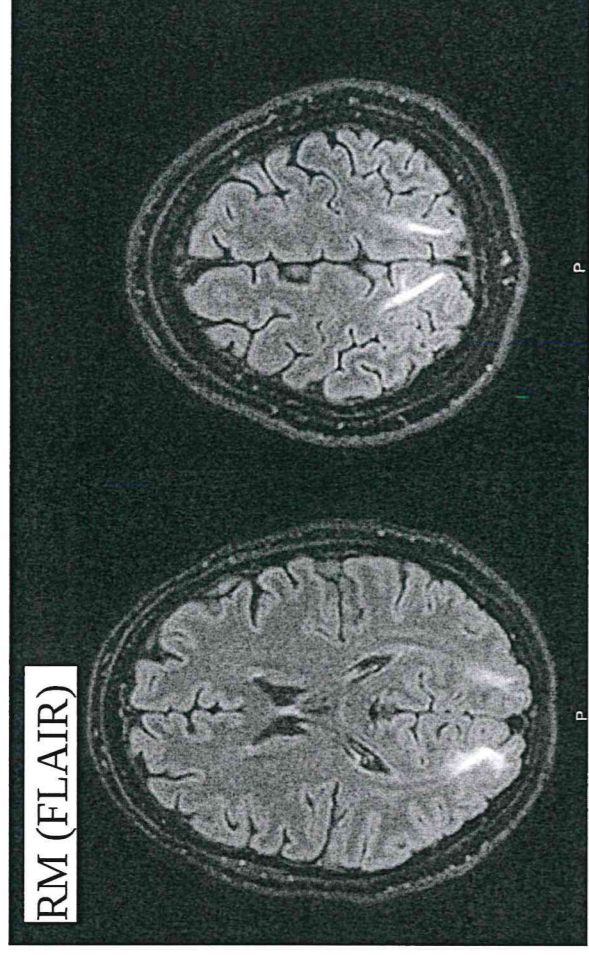
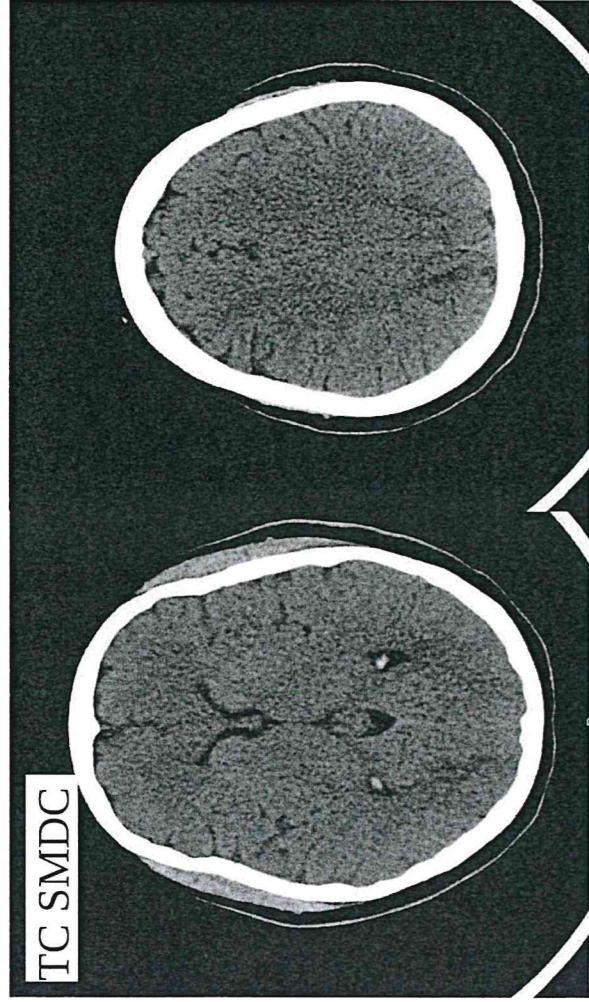

From Patient 25

Allegato n.2

1



Donna 28 aa. in gravidanza (38 settimane + 6 gg)

Dolori diffusi

Nega terapie in atto

vigile orientata non deficit neurologici focali non segni meningei
addome trattabile non dolente

6 giorni dopo ritorno in PS

Cefalea

crisi epilettica generalizzata con stato soporoso postcritico

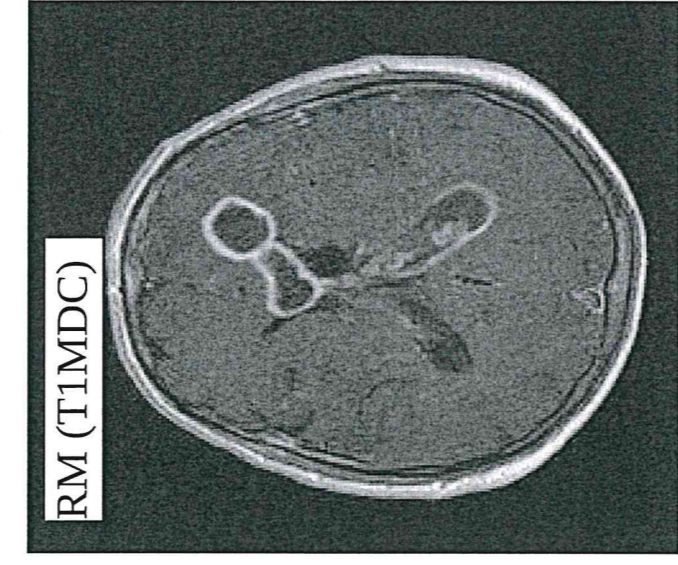
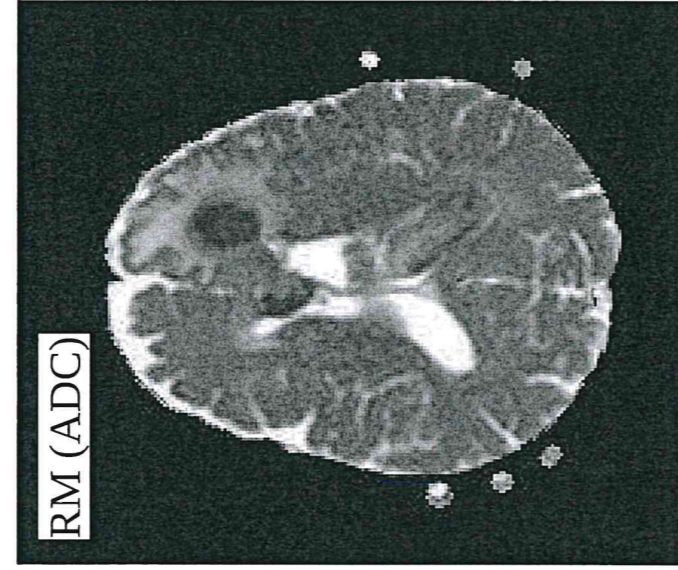
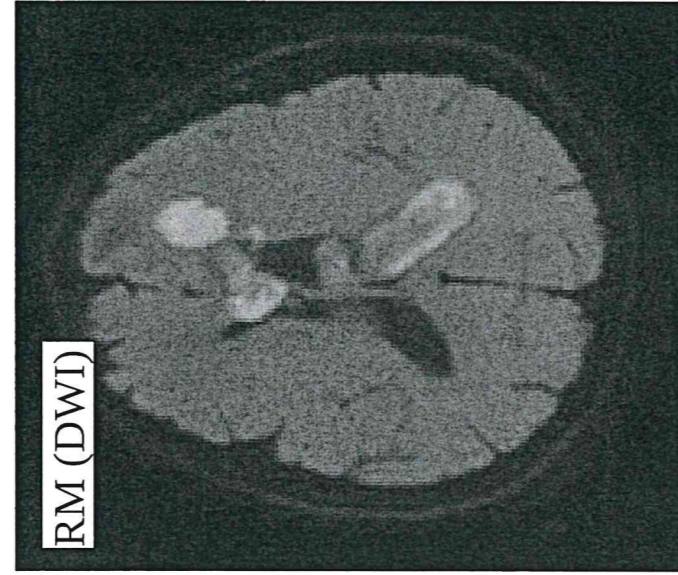
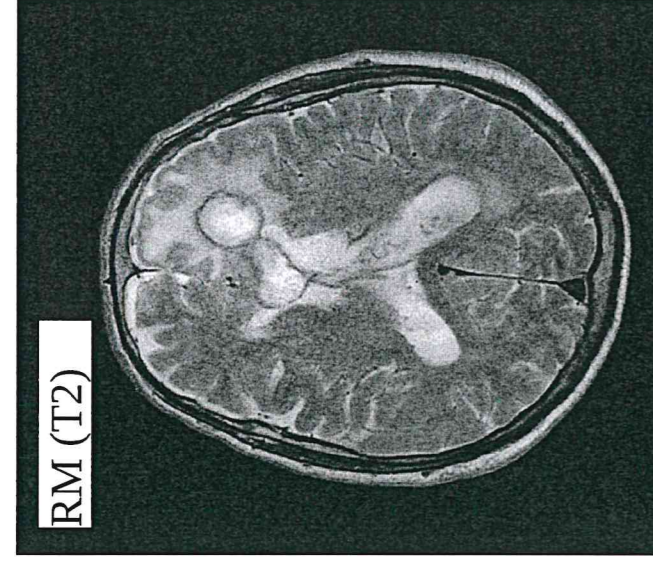
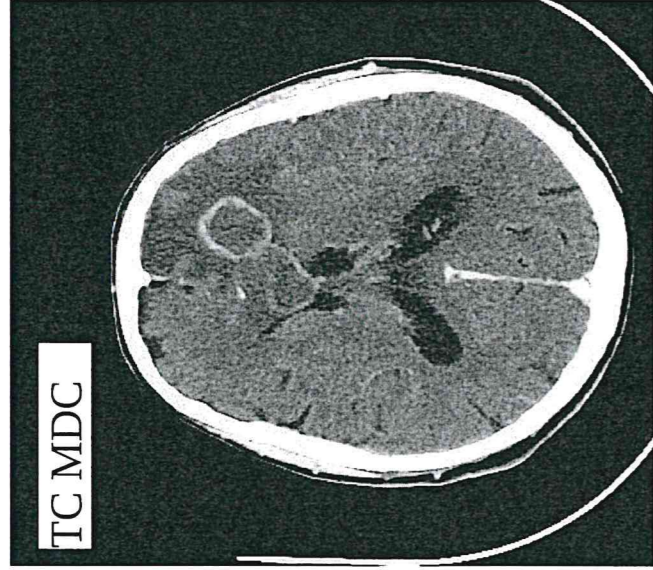
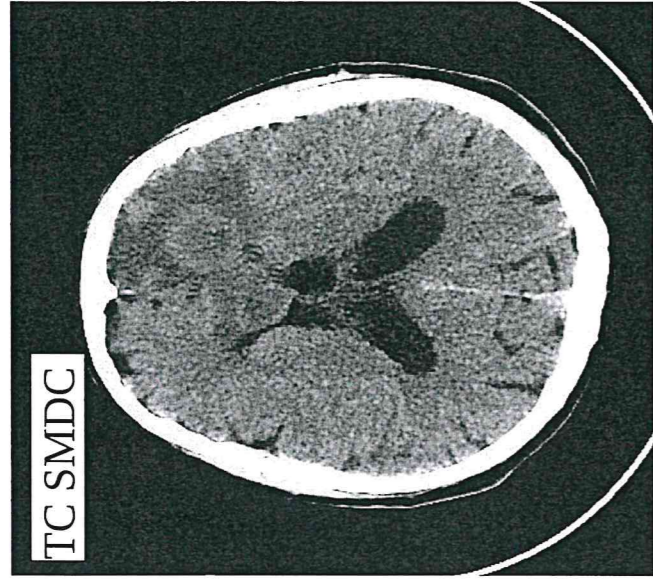
ACV valida e ritmica

AR non segni di stasi e/o stenosi

AR

fc
caep / now

26
Prax
2



Uomo 75 aa.
Stato soporoso, confuso, iperpiretico
APR muta
EO torace: negativo
addome trattabile non dolente

R
fda novo
coll